



Neobladder “Belgrade pouch”: Metabolic consideration

Neobešika *Belgrade pouch*: metabolička razmatranja

Vladimir Bančević*[†], Predrag Aleksić*[†], Dušica Stamenković^{†‡},
Tomislav Pejčić[§], Novak Milović*[†], Božidar Kovačević^{||}, Snežana Cerović^{†||}

*Urology Clinic, [‡]Clinic for Anesthesiology and Intensive Care, ^{||}Institute for Pathology,
Military Medical Academy, Belgrade, Serbia; [†]Faculty of Medicine of the Military
Medical Academy, University of Defence, Belgrade, Serbia; [§]Urology Clinic, Clinical
Center of Serbia, Belgrade, Serbia

Abstract

Background/Aim. The ileal neobladder should be a low-pressure reservoir with acceptable volume and relatively small resorptive surface. A larger inner surface of the ileal pouch is associated with the high resorption of urine metabolites through intestinal mucosa and systemic metabolic disturbances, while a too small pouch results in a higher frequency of voiding and incontinency. The aim of this study was to investigate it is possible to create a neobladder from a shorter ileal segment compared to standard surgical techniques, and reduce metabolic complications. **Methods.** This prospective study included 77 male patients, scheduled for radical cystectomy and orthotopic neobladder derivation. The patients were divided into two groups: the standard pouch (SP) group of 37 patients scheduled for standard orthotopic neobladder, using a 50–70 cm long terminal ileum segment; the “Belgrade pouch” (BP) group of 40 patients scheduled for original, orthotopic urinary reservoir, using a 25–35 cm long terminal ileum segment. We measured neobladder capacity, acidosis, base excess and bicarbonate concentration in the postoperative month 3rd, 6th, 12th and 15th. **Results.** At the end of the study, the patients from the SP group had much higher neobladder capacity than the natural bladder – 750 mL (range 514–2,050 mL); in contrast, the patients from the BP group had average capacity of 438 mL (range 205–653 mL) ($p < 0.001$). At the end of the study, there were more patients with acidosis (37.8% : 2.5%), base excess (35.1% : 7.5%) and low bicarbonate level (40.5% : 20.0%) in the SP group, than in the BP group, respectively ($p < 0.001$). **Conclusion.** “Belgrade pouch”, make from 25–35 cm long terminal ileum segment may obtain adequate capacity and lower rate of metabolic disturbances than standard, high capacity orthotopic neobladders.

Key words:

urinary bladder neoplasms; urologic surgical procedures; colonic pouches; serbia; metabolism.

Apstrakt

Uvod/Cilj. Ilealna neobešika trebalo bi da bude rezervoar niskog pritiska, adekvatnog kapaciteta i relativno male resorptivne površine. Velika unutrašnja površina neobešike napravljene od tankog creva rezultuje apsorpcijom urina kroz crevnu sluznicu neobešike, što može da dovede do ozbiljnih sistemskih metaboličkih komplikacija. Sa druge strane, izrada neobešike malog kapaciteta može da rezultuje učestalim mokrenjem i inkontinencijom. Cilj ove studije bio je da se utvrdi da li je moguće napraviti neobešiku od kraćeg crevnog segmenta u odnosu na standardne tehnike i time smanjiti metaboličke postoperativne komplikacije. **Metode.** U ovu prospektivnu studiju bilo je uključeno 77 bolesnika muškog pola, koji su bili podvrgnuti radikalnoj cistektomiji i ortotopnoj ilealnoj derivaciji urina. Bolesnici su bili podeljeni u dve grupe: SP grupa koju je činilo 37 bolesnika standardnom ortotopnom neobešikom (*standard pouch*) od segmenta terminalnog ileuma dužine 50–70 cm; BP grupa od 40 bolesnika sa originalnom neobešikom (“*Belgrade pouch*”) od kraćeg crevnog segmenta dužine 25–30 cm. Praćeni su sledeći parametri: kapacitet neobešike, acidoza, bazni eksces i koncentracija bikarbonatnih jona u krvi, 3, 6, 12 i 15 meseci nakon operacije. **Rezultati.** Na kraju studije, bolesnici iz SP grupe imali su značajno veći kapacitet neobešike [750 (514–2 050) mL] od nativne mokraćne bešike i od neobešike BP grupe [438 (205–653 mL)] ($p < 0,001$). Takođe, na kraju studije, rezultati su pokazali da su se u SP grupi u odnosu na BP grupu, statistički značajno češće javljali acidoza (37,8% : 2,5%) i bazni eksces (35,1% : 7,5%), a zabeležene su i niže vrednosti koncentracije bikarbonatnih jona u krvi (40,5% : 20,0%) ($p < 0,001$). **Zaključak.** “*Belgrade pouch*” od kraćeg ilealnog segmenta dužine 25–35 cm omogućava odgovarajući kapacitet neobešike i smanjuje broj i učestalost metaboličkih komplikacija u poređenju sa standardnom tehnikom neobešike uz upotrebu dužeg crevnog segmenta.

Ključne reči:

mokraćna bešika, neoplazme; hirurgija, urološka, procedure; creva, rezervoari; srbija; metabolizam.

Introduction

Longer than one century, urological surgeons are trying to find an ideal substitute for the urinary bladder in patients who require cystectomy¹. Radical cystectomy still represents a golden standard for the treatment of muscle-invasive, organconfined bladder cancer in clinical stages T2–T4a, N0–Nx². The creation of the new urinary bladder, so-called neobladder, or urinary pouch, should meet the following criteria: a neobladder should be a low-pressure reservoir, with acceptable volume and relatively small resorptive surface. The large inner surface of a pouch is associated with the high resorption of urine metabolites through intestinal mucosa and systemic metabolic disturbances³.

There are over 40 different types of orthotopic neobladders; however, the most frequently created are neobladders made from 45–70 cm long segment of the terminal ileum^{4,5}. Unfortunately, during the time, the capacity of the neobladder increases, even up to eight times, which is followed by the increase of the resorptive surface of the pouch^{6–8}. There are several consequences of that phenomenon: poor emptying of the reservoir, deterioration of the upper urinary tract, and metabolic complications. Metabolic complications are the most frequent late complications of the neobladder formation, so, every procedure which decreases their frequency and severity is of major importance.

Nowadays the management of patients with malignancy should offer not only the most curable oncological procedure, but a high level of quality of life whenever it is possible. The “Belgrade pouch” is a small step in that direction.

Methods

This prospective clinical study included 77 patients who had underwent radical cystectomy and orthotopic neobladder, from 2003 to 2012 in the Military Medical Academy, Clinic of Urology in Belgrade, Serbia. All the patients had muscle-invasive transitional cell carcinoma (TCC) of the bladder. This study was a part of the larger research ongoing project “The modification of orthotopic intestinal urine reservoir after radical cystectomy“. The patients were divided into two groups. The first one was the standard pouch (SP) group of 37 patients with cystectomy and standard orthotopic neobladder, made from 50–70 cm long terminal ileum segment. The techniques used in this group were described and named by their authors (Hautmann, Camey II, Studer). The second group was the “Belgrade-pouch” (BP) group of 40 patients with cystectomy and the original, modified orthotopic neobladder, created from 25–35 cm long terminal ileum segment, in the form of the letter “U”. Minimal mesenterial incision and direct ureterointestinal anastomosis were performed. Uretero-pouch anastomosis was performed with 6 (5–7) stitches, and traction of 0.5 kg on the urinary catheter was administrated for two days. Twice a day we flashed neobladder with 20 mL 0.9% NaCl solution until the catheter was removed.

All the patients underwent the measurement of neobladder capacity and arterial blood pH, base excess and bicar-

bonate concentration. Measurements were repeated in the postoperative months 3, 6, 12 and 15.

Patients with disease progression, diabetes mellitus, chronic obstructive pulmonary disease and patients receiving postoperative chemotherapy were excluded from the study. All the patients underwent the following arterial blood analyses: pH level, base excess (BE) and bicarbonate ion concentration (HCO_3^-) preoperatively and in postoperative months 3, 6, 12 and 15. The values of the parameters from the arterial blood that were considered abnormal were: $\text{pH} < 7.35$, $\text{BE} > 2$ and $\text{HCO}_3^- < 22$ mmol/L.

For the minimal number of examinees *per* group (24 patients) and coefficient $\alpha = 0.05$, the power of the study ($1 - \beta$) was over 80%.

Results

The patients from the SP group had a significantly higher neobladder capacity than the patients from the BP group, during the whole follow-up ($p < 0.001$). In addition, at the end of the study, the patients from the SP group had much higher neobladder capacity than the natural bladder (750 mL, range: 514–2050 mL), while the patients from the BP group had the average capacity of 438 mL (range: 205–653 mL). At the end of the study, there were more patients with acidosis (37.8% : 2.5%), base excess (35.1% : 7.5%) and low bicarbonate level (40.5% : 20.0%) in the SP group than in the BP group, respectively ($p < 0.001$) (Figures 1 and 2).

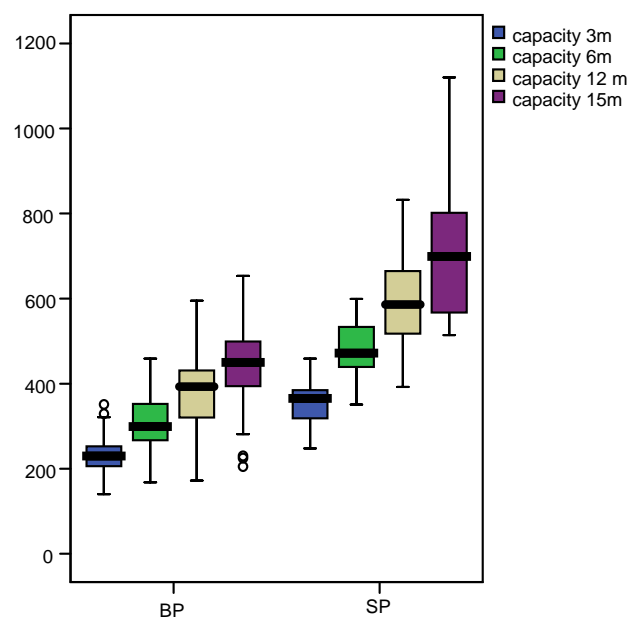


Fig. 1 – Increasing of pouch capacity in the “Belgrade pouch” (BP) and standard pouch (SP) groups. (m – postoperative month).

Variance analysis confirmed significantly different values for neobladder volume in the groups SP and BP ($F = 113.612$; $p < 0.001$; $\text{Eta}^2 = 0.609$). The neobladder capacity increased significantly over time in both groups. The

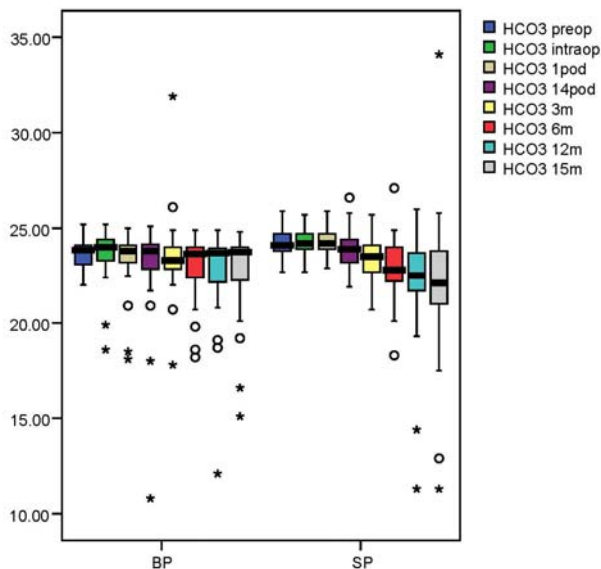


Fig. 2 – Decreasing of HCO₃⁻ concentration in the “Belgrade pouch” (BP) and standard pouch (SP) group during the time.
 preop – preoperatively;
 intraop – intraoperatively;
 pod – postoperative day;
 m – postoperative month.

There were statistically significant differences between the two groups in the change of pH ($F = 15.428$; $p = 0.000$; $Eta^2 = 0.171$), the values of BE ($\chi^2 = 4.439$; $df = 1$; $p = 0.035$) and the change in HCO₃⁻ concentration ($F = 2.791$; $p = 0.045$; $Eta^2 = 0.036$). However, the most significant differences appeared after the postoperative month 15 (Figure 3).

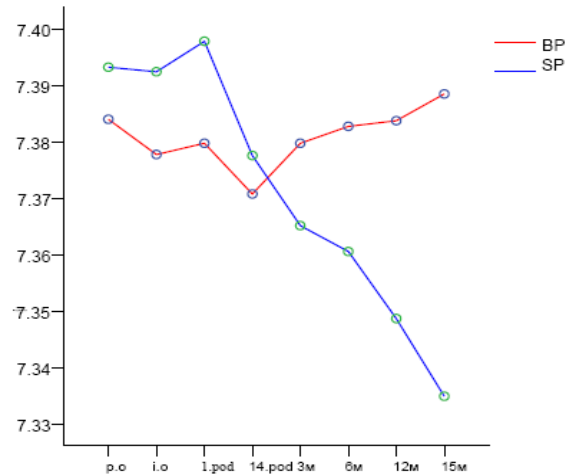


Fig. 3 – Level of acidosis in the “Belgrade pouch” (BP) and standard pouch (SP) groups; po – preoperatively; io – intraoperatively; m – postoperative month; pod – postoperative day. There was no significant change of pH in the BP group at the end of the study.

length of the intestinal segment had a very significant influence on the change of the neobladder capacity ($F = 31.840$; $p = 0.000$; $Eta^2 = 0.304$). The results are shown in Table 1.

Table 1

Metabolic parameters of the BP and SP groups					
Parameter	Time	BP	SP	<i>p</i>	Statistics
Male gender, (% of patients)	-	82.5	88.9	0.429	$\chi^2 = 0.625$; $df = 1$
Age (years), mean (range)	-	61.66 (42–47)	59.11 (40–73)	0.202	$t = 1.288$; $df = 72$;
Length of terminal ileum (cm), mean (range)	-	28.9 (20–35)	57.5 (50–70)	< 0.001**	Mann Whitney Z = -7.588
Neobladder capacity (mL), mean (range)	3 m	237 (150–351)	358 (248–459)	< 0.001**	Variance analysis
	6 m	312 (168–459)	486 (351–599)	< 0.001**	
	12 m	372 (172–558)	598 (392–832)	< 0.001**	
	15 m	438 (205–653)	750 (514–2050)	< 0.001**	
Acidosis (% of patients)	14 pod	10	0	0.144	$\chi^2 = 2.136$; $df = 1$
	3 m	0	10.8	0.105	$\chi^2 = 2.630$; $df = 1$
	6 m	2.5	10.8	0.310	$\chi^2 = 1.032$; $df = 1$
	12 m	2.5	32.5	0.001**	$\chi^2 = 12.272$; $df = 1$
	15 m	2.5	37.8	0.001**	$\chi^2 = 15.302$; $df = 1$
BE (% of patients)	14 pod	15.0	8.1	0.558	$\chi^2 = 0.343$; $df = 1$
	3 m	15.0	21.6	0.452	$\chi^2 = 0.567$; $df = 1$
	6 m	12.5	24.3	0.179	$\chi^2 = 1.806$; $df = 1$
	12 m	12.5	32.4	0.035	$\chi^2 = 4.439$; $df = 1$
	15 m	7.5	35.1	0.003	$\chi^2 = 8.917$; $df = 1$
Decrease in the level of bicarbonats (% of patients)	14 pod	10.0	2.7	0.403	$\chi^2 = 0.698$; $df = 1$
	3 m	5.0	16.2	0.216	$\chi^2 = 1.532$; $df = 1$
	6 m	12.5	13.5	> 0.05	$\chi^2 = 1.122$; $df = 1$
	12 m	15.0	29.7	0.119	$\chi^2 = 2.424$; $df = 1$
	15 m	20.0	40.5	0.048*	$\chi^2 = 3.871$; $df = 1$

BP – Belgrade pouch; SP – standard dimensioned pouch; BE – base excess; pod – postoperative day; m – postoperative month; *statistically significant difference; **statistically highly significant difference.

Discussion

Some of the pioneers in the field of orthotopic neobladder, like Hautmann et al.⁹, advocated the use of 60–70 cm long segment of the terminal ileum, for the creation of the reservoir. They considered that the neobladder required sufficient capacity for the acceptable urine continence. In contrast, some of the most important European urologists, like Hautmann et al.⁹ and Studer et al.¹⁰, advocate the use of shorter intestinal segments, in order to avoid unnecessary large capacity and numerous consequent metabolic disorders. They found that the best neobladder capacity was about 450 mL¹¹. In addition, Sevin et al.¹¹ and Constantinides et al.¹² published acceptable functional results, using short, 36–40 cm long terminal ileal segment.

In our study, the average length of the terminal ileal segment was 28.9 cm. Like other studies, our study proved that the capacity of standard neobladders overcame the capacity of the natural urinary bladder after the postoperative month 12. However, “Belgrade-pouch” neobladders reached natural bladder capacity from postoperative month 9 to 12. In the BP group, the graduate increase of the capacity was slow, providing a high level of continence, which was previously described. In previous papers we reported that “Belgrade pouch” obtains clinically insignificant postvoided residual urine, no significant hydronephrosis due to uretero-pouch reflux, and reasonable frequency^{13,14}.

A high percent of patients with classical neobladder, 25–50%, have acidosis¹⁵. Some authors believe that this percent could be lower if the intestinal segment was shorter than 45 cm^{16,17}. The authors of this work think that the length of the ileal segment should have been even shorter, about 30 cm, to provide the low rate of metabolic complications, with the acceptable capacity and continence.

Usually, patients with acidosis experience a long period without the symptoms; however, after that, they are prone to serious, even life-threatening complications. In 6% of cases, acute metabolic disorders require the treatment in the intensive care unit^{15,16}. In our study, there was a modest decrease in pH value on the postoperative day 14: it could be ex-

plained by the fact that it was the time when urinary catheter is usually removed. After the catheter removal, the walls of the pouch stretch and the urine comes in longer contact with intestinal mucosa. After this period, acidosis was noted in only 2.5% of patients in the BP group, while in the SP group that percent was constantly increasing, parallel to the increase of the neobladder capacity. The average pH value in the BP group was inside the normal range (7.35–7.45), while in the SP group, the average pH value was lower than 7.35 after the month 12.

Base excess is a good indicator of metabolic acidosis or alkalosis¹⁷. In the SP group, the percentage of patients with absolute BE > 2 increased constantly; in the BP group, significantly smaller percentage of patients had BE out of normal range. In both groups, the average BE values were constantly increasing with time; however, the patients from the SP group had significantly higher average BE values than the patients in BP group, after the month 3 of follow-up. The average BE values also confirm that neobladders created from shorter ileal segments are better substitute for the natural bladder.

At last, the number of patients with bicarbonate concentration lower than 22 mmol/L was constantly increasing in both groups. However, the statistical difference between the groups appeared only after the month 15 of follow-up. The average bicarbonate concentration was decreasing faster in the SP group, than in the BP group.

The results from our study, concerning BE values and HCO₃⁻ concentration after orthotopic neobladder formation, were in concordance with other published papers¹⁷. However, only few authors were dealing with this problem.

Conclusion

“Belgrade-pouch”, orthotopic neobladder created by the original technique with a very short ileal segment, is characterized by smaller capacity and resorptive surface than standard dimensioned pouch. It provides better quality of life and lessens the percentage of patients suffering from acidosis, base excess and bicarbonate deficiency than standard neobladder.

REFERENCES

1. Coffey RC. Physiologic implantation of the severed ureter or common bile duct into the intestine. *JAMA* 1911; 56(6): 397.
2. Chin JL. The quest for a better bladder from bowel. *Eur Urol* 2011; 59(4): 524–5.
3. Witjes JA, Compérat E, Cowan NC, De Santis M, Gakis G, Lebet T, et al. EAU guidelines on muscle-invasive and metastatic bladder cancer: summary of the 2013 guidelines. *Eur Urol* 2014; 65(4): 778–92.
4. Stein JP, Skinner DG. Orthotopic urinary diversion. In: Walsh P, editor. *Campbell-Walsh Urology*, 8th ed. Philadelphia: W.B. Saunders; 2002. p. 3835–64.
5. Hautmann RE, Eggbart G, Frohneberg D, Miller K. The ileal neobladder. *J Urol* 1988; 139(1): 39–42.
6. Kulkarni JN, Pramesh CS, Rath S, Pantvaidya GH. Long-term results of orthotopic neobladder reconstruction after radical cystectomy. *BJU Int* 2003; 91(6): 485–8.
7. Burkhard FC, Kessler TM, Mills R, Studer UE. Continent urinary diversion. *Cit Rev Oncol Hem* 2006; 57(3): 255–64.
8. Thurai Raja R, Burkhard FC, Studer UE. The orthotopic neobladder. *BJU Int* 2008; 102(9 Pt B): 1307–13.
9. Hautmann RE, Botto H, Studer UE. How to obtain good results with orthotopic bladder substitution: the 10 commandments. *Eur Urol Suppl* 2009; 8: 712–7.
10. Studer UE, Burkhard FC, Schumacher M, Kessler TM, Thoeny H, Fleischmann A, et al. Twenty years experience with an ileal orthotopic low pressure bladder substitute—lessons to be learned. *J Urol* 2006; 176(1): 161–6.

11. *Sevin G, Soyupek S, Armağan A, Hoşcan MB, Oksay T.* Ileal orthotopic neobladder (modified Hautmann) via a shorter detubularized ileal segment: experience and results. *BJU Int* 2004; 94(3): 355–9.
12. *Constantinides C, Manousakas T, Chrisofos M, Giannopoulos A.* Orthotopic bladder substitution after radical cystectomy: 5 years of experience with novel personal modification of the ileal pouch. *J Urol* 2001; 166(2): 532–7.
13. *Bančević V, Aleksić P, Milović N, Košević B, Čampara Z, Stamenković D.* Post-voiding residual urine and capacity increase in orthotopic urinary diversion-standard vs. modified technique. *Vojnosanit Pregl* 2010; 67(7): 558–61. (Serbian)
14. *Aleksić P, Bancević V, Milović N, Kosević B, Stamenković DM, Karanikolas M, et al.* Short ileal segment for orthotopic neobladder: a feasibility study. *Int J Urol* 2010; 17(9): 768–73.
15. *Stein JP, Dunn MD, Quek ML, Miranda G, Skinner DG.* The orthotopic T pouch ileal neobladder: experience with 209 patients. *J Urol* 2004; 172(2): 584–7.
16. *Fletcher S, Dbrampal A.* Acid-Base Balance and Arterial Blood Gas Analysis. *Surgery (Oxford)* 2003; 21(3): 61–5.
17. *Fujisawa M, Nakamura I, Yamanaka N, Gotob A, Hara I, Okada H, et al.* Changes in calcium metabolism and bone demineralization after orthotopic intestinal neobladder creation. *J Urol* 2000; 163(4): 1108–11.

Received on January 13, 2015.

Accepted on April 14, 2015.

Online First April, 2016.